

## PennHIP Report

Referring Veterinarian: Dr Keith Clement Email: reception@burnthillsvethosp.com	Clinic Name: Burnt Hills Veterinary Hospital Clinic Address: 145 Goode Street Burnt Hills, NY 12027 Phone: (518) 399-5213 Fax: (518) 399-3370
--	---

## Patient Information

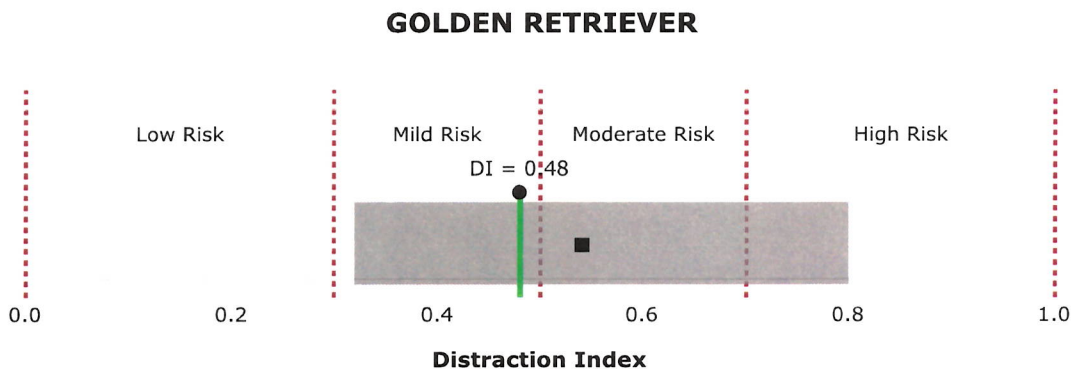
Client: MOORE, Greg Patient Name: GEORGE Reg. Name: King George Of Windy Knoll Goldens PennHIP Num: 145880 Species: Canine Date of Birth: 30 Jan 2020 Sex: Male Date of Study: 20 Aug 2020 Date of Report: 22 Aug 2020	Tattoo Num: Patient ID: 32151GEORGE Registration Num: SS17667304 Microchip Num: Breed: GOLDEN RETRIEVER Age: 7 months Weight: 62 lbs/28.1 kgs Date Submitted: 21 Aug 2020
--	--

## Findings

Distraction Index (DI): Right DI = 0.46, Left DI = 0.48. Osteoarthritis (OA): No radiographic evidence of OA for either hip. Cavitation/Other Findings: No cavitation present.
--

## Interpretation

Distraction Index (DI): The laxity ranking is based on the hip with the greater laxity (larger DI). In this case the DI used is 0.48.  
OA Risk Category: The DI is between 0.31 and 0.49. This patient is at mild risk for hip OA.  
Distraction Index Chart:



**BREED STATISTICS:** This interpretation is based on a cross-section of 21419 canine patients of the GOLDEN RETRIEVER breed in the AIS PennHIP database. The gray strip represents the central 90% range of DIs (0.32 - 0.80) for the breed. The breed average DI is 0.54 (solid square). The patient DI is the solid circle (0.48).

**SUMMARY:** The degree of laxity (DI = 0.48) falls within the central 90% range of DIs for the breed. This amount of hip laxity places the hip at a mild risk to develop hip OA. **No radiographic evidence of OA for either hip.**