

PennHIP Report

Referring Veterinarian: Dr Dave Cloutier	Clinic Name: Veazie Veterinary Clinic
Email: veaziev@veaziev.com	Clinic Address: 1522 State St. Veazie, ME 04401
	Phone: (207) 941-8840
	Fax:

Patient Information

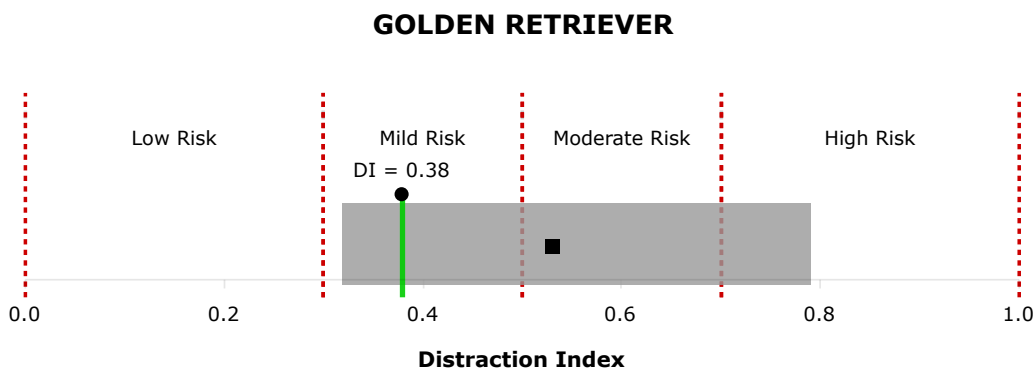
Client: Moore, Greg	Tattoo Num:
Patient Name: Liberty	Patient ID: 372741B
Reg. Name:	Registration Num:
PennHIP Num: 195208	Microchip Num:
Species: Canine	Breed: GOLDEN RETRIEVER
Date of Birth: 24 Jul 2021	Age: 27 months
Sex: Female	Weight: 50 lbs/22.7 kgs
Date of Study: 31 Oct 2023	Date Submitted: 31 Oct 2023
Date of Report: 01 Nov 2023	

Findings

Distraction Index (DI): Left DI = 0.38, the right DI was not computed.
 Osteoarthritis (OA): **No radiographic evidence of OA for either hip.**
 Cavitation/Other Findings: Cavitation was present on the right hip. Cavitation is harmless to the hip, however it can artificially and temporarily increase the distraction index. Therefore, no laxity score is provided for the right hip.

Interpretation

Distraction Index (DI): One hip cannot be used for the laxity ranking (see Findings). The opposite hip will be used in the analysis. The value of the DI is 0.38.
 OA Risk Category: The DI is between 0.31 and 0.49. This patient is at mild risk for hip OA.
 Distraction Index Chart:



BREED STATISTICS: This interpretation is based on a cross-section of 26170 canine patients of the GOLDEN RETRIEVER breed in the AIS PennHIP database. The gray strip represents the central 90% range of DIs (0.32 - 0.79) for the breed. The breed average DI is 0.53 (solid square). The patient DI is the solid circle (0.38).

SUMMARY: The degree of laxity (DI = 0.38) falls within the central 90% range of DIs for the breed. This amount of hip laxity places the hip at a mild risk to develop hip OA. **No radiographic evidence of OA for either hip.**